류마티스 관절염의 슬관절 수술적 치료
Surgical management of the knee in rheumatoid arthritis

이명철, 한일규
서울대학교 의과대학 정형외과학 교실

Myung Chul Lee, M.D., Ph.D. and Ilkyu Han, M.D.
Department of Orthopaedic Surgery, Seoul National University College of Medicine
주소: 서울시 종로구 연건동 28 서울대학병원 정형외과학 교실
Tel: 82-2-2072-2368, Fax: 82-2-764-2718
Email: leemc@snu.ac.kr

초 록

관절의 구조적인 손상으로 인한 심한 무릎의 통증과 기능의 제한은 수술적인 치료로 효과를 얻을 수 있다. 무릎 관절은 류마티스 관절염 환자에서 가장 흔히 수술적으로 치료하는 관절 중 하나이다. 류마티스 관절염에 이환된 무릎에 행해지는 수술로는 활액막 절제술, 관절 유합술, 인공 슬관절 전치환술 등이 있다.

활액막 절제술은 골이나 연골의 파괴 없이 관절에서 염증이 심한 활액막으로 인한 증상이 있을 때 시행될 수 있다. 관혈적 혹은 관절경적 활액막 절제술 모두에서 비교적 좋은 결과가 보고되고 있다. 골이나 연골의 손상이 있는 류마티스 관절염 환자에서 가장 좋은 수술 방법은 인공 슬관절 전치환술이다. 대부분의 환자에서 통증의 소실과 기능의 향상을 기대할 수 있으며 10년 이상의 인공관절의 수명을 기대할 수 있다. 젊은 환자 중에서 육체 노동이 많이 필요한 환자에서 경우에 따라 관절 유합술을 시행하기도 한다.

류마티스 관절염에 이환된 무릎 관절에서 적절한 시기에 수술적인 치료로 좋은 결과를 기대할 수 있다. 좋은 결과를 얻기 위해서는 환자의 치료에 참여하고 있는 정형외과 의사와 내과 의사간의 긴밀한 협조가 필요하다.

Key words: rheumatoid arthritis, surgical management, knee, arthroplasty

Introduction

Pharmacologic treatment remains the mainstay of treatment of patients with rheumatoid arthritis (RA). Numerous advances in the medical treatment of RA have decreased the need for operative intervention. However, in patients who have unacceptable levels of pain, loss of range of motion, or limitation of function because of structural damage, surgical treatment should be considered.[1] Wolfe *et al*.[2] reported that 25 % of RA patients will eventually undergo total joint arthroplasty after 22 years of disease onset.

Determining the need for and optimum time of operative intervention requires a close working relationship between the orthopedic surgeon and the physician. Compromised surgical results may occur if an advanced disease state creates bony destruction and severe soft tissue contracture of the involved joint.

One of the joints that is frequently treated surgically is the knee.[2] Knee involvement is uncommon during the early stages of rheumatoid arthritis. However, one or both knees will be affected ultimately in approximately 90% of individuals with chronic RA. Both knees are involved in 65-70% of cases.[3] This review will discuss the indications and the results of surgical methods currently being used for the treatment of the knee joint in RA patients. The latest developments in the surgical treatment of the knee joint in RA patients will also be described.

Synovectomy

RA is a systemic disease that affects the synovium primarily[1]. Initial pharmacologic agents are aimed controlling the inflammatory process of the synovium. When these pharmacologic agents have failed to address the pain and disability from the inflamed

synovium, synovectomy may be performed.

1) Indications

RA patients with synovitis causing pain and disability that has not responded to 6 months of pharmacologic treatment are good candidates for synovectomy. Synovectomy appears most effective when it is done early, in stage I (without bone involvement) or stage II (with minimal bone involvement).[4] In patients with stage III changes with evidence of bone and cartilage destruction, synovectomy still can be effective for pain relief and joint mobility, but results are inferior to those done for stage I or II diseases.

2) Results

Open synovectomy requires an arthrotomy with radical debridement and provides short-term pain relief. However, the post-operative recovery may be difficult and complicated due to knee stiffness. Doets *et al*.[4] reported that half of the patients who had open synovectomy in the early stages of the disease had short-term satisfactory results.

Arthroscopic synovectomy is becoming a more popular method of treatment because of short patient recovery time and fewer complications than open synovectomy. Smiley *et al*.[5] reported that arthroscopic synovectomy yielded results similar to those reported for open synovectomy. 81% of his patients showed no radiologic deterioration after 4 years of follow-up. In a multicenter study by Klug *et al*.[6], 93 knees with early RA were treated with arthroscopic synovectomy with an average follow-up of 33 months. The increase in knee scores confirmed a significant improvement in pain and function after arthroscopic synovectomy. After a mean follow-up of 8 years, Gibbons *et al*.[7] concluded that arthroscopic synovectomy in appropriately selected patients with RA is a safe and reliable procedure with a low complication rate.

Arthrodesis

Arthrodesis frequently is used for salvage of destroyed joints in patients with RA, especially in the interphalangeal joints of the hand, metacarpo-phalangeal joint of the thumb, the wrist, the ankle, the hind foot, the metatarsophalangeal joint of the great toe and the first and second cervical vertebrae.[8] However, the patient' s and surgeon' s enthusiasm for the arthrodesis procedure for the knee joint has markedly diminished. From the standpoint of the patient, with the knowledge of the remarkable results of total knee arthroplasty (TKA), the concept of stiff straight leg is not appealing. Unlike the successful transition from hip fusion to total hip arthroplasty, surgeons are well aware of the fact the conversion of knee fusion to TKA has had only limited success.

1) Indications

Young motivated patients who plan to continue to perform manual labor for a livelihood may be considered for arthrodesis. However, all other surgical and non-surgical options should be exhausted before arthrodesis.

2) Results

Figgie *et al*.[9] reported successful fusion in 20 of 27 patients with failed TKA' s. Better results can be anticipated with primary knee fusion in RA patients.

Total knee arthroplasty

In some patients, the synovitis of rheumatic knee progresses to articular cartilage destruction, and in some cases, leads to bone loss and ligamentous insufficiency. Total knee arthroplasty (TKA) is the procedure of choice in these patients.

1) Indications

RA patients with evidence of bone and cartilage destruction are best treated with TKA. If synovitis is the cause of the patient' s pain and disability, continued medical treatment or synovectomy may be appropriate. However, if it is certain that structural

damage to the joint is the problem, medication or synovectomy will not be sufficient.

2) Results

For predictable relief of knee pain and restoration of knee function, TKA has revolutionized the outlook for RA patients. Pain relief is either complete or nearly so in more than 95% of patients.[10] Although many patients gain a lot of functional improvement after undergoing TKA, the degree of functional improvement obtained is somewhat less certain. The degree of functional improvement obtained is related to the patient' s preoperative functional level, mental health status and the health care system which can provide an effective postoperative rehabilitation program.[11] Postoperative rehabilitation should start with range of motion exercise, muscle strengthening exercise and then proceed with exercises for achieving daily functional activities.

The long-term survivorship of TKA in RA patients has been excellent with several series reporting 10 year prosthesis survivorship in greater than 85% of the patients.[12-14] Rand *et al*.[15] reported a higher survivorship of TKA in patients with RA than in patients with osteoarthritis (OA) (83% versus 80%). Nafei *et al*.[13], however, documented an 87% survivorship of TKA for RA patients versus a 97% survivorship of TKA for OA patients at 12 years follow-up. Other series have reported no significant differences when comparing the two groups of patients.[16,17]

Latest developments in TKA

Minimally invasive TKA

The most popular incision used to open the joint capsule during TKA has been the median parapatellar approach, with separation of the vastus medialis from the rectus femoris and eversion of the patella. Despite excellent results, recuperation from TKA using this type of approach has often been painful and arduous for patients. Recently, minimally invasive approach[18], which uses a smaller capsular incision that does not violate the extensor mechanism extensively, has been developed (Figure 1). Faster recuperation and less pain can be expected from this approach.

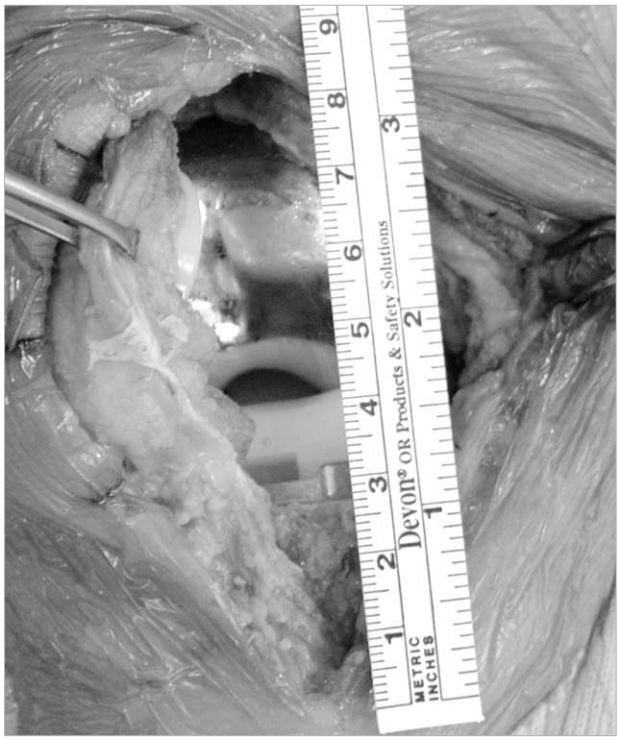

Figure 1 . Small skin Incision before wound closure after minimally invasive total knee arthroplasty.

RA patients, compared to OA patients, who may have to undergo a more difficult rehabilitation process because of the polyarticular and systemic nature of the disease, may especially benefit from minimally invasive TKA. However, adequate exposure of the joint for total synovectomy, which is recommended especially if active synovitis is present, may not be feasible. Patients with RA are on average 10 years younger than patients with OA at the time of TKA[19]. TKA in RA patients will need to be functional for a longer time. Proper TKA component positioning and soft tissue balancing, which is important for longevity and function of TKA, becomes especially important for RA patients undergoing TKA. Improper component placement and soft tissue balancing, due to limited exposure of minimally invasive approach, may turn out to have a more detrimental effect on the outcome of TKA in RA patients.

Computer assisted TKA

Computer assisted TKA have been developed to improve the accuracy of the component positioning and soft tissue balancing. By using the computer assisted navigation, errors in component positioning and soft tissue balancing could be reduced. The reduction in errors is especially important for RA patients because of the younger age at the time of TKA.

Conclusion

RA patients who have unacceptable levels of pain, limitation of function of the knee joint, surgical treatment should be considered. The results of surgical treatments depend on the proper decision and timing of operative intervention. A close working relationship between the orthopedic surgeon and the physician is required for a successful outcome.

References

1. American collegy of rheumatology subcommittee on rheumatoid arthritis guidelines. Guidelines for the management of rheumatoid arthritis. Arthritis Rheum 2002; 46: 328-46.
2. Wolfe F, Zwillich SH. The long-term outcomes of rheumatoid arthritis: a 23-year prospective, longitudinal study of total joint replacement and its predictors in 1,600 patients with rheumatoid arthritis. Arthritis Rheum 1998; 41: 1072-82.
3. Fleming A, Crown JM, Corbett M. Early rheumatoid diasease. I,Onset. Ann Rheum Dis 1976; 35: 357-60.
4. Doets HC, Bierman BT, Soesbergen RM. Synovectomy of the rheumatoid knee does not prevent deterioration. 7-year follow-up of 83 cases. Acta Orthop Scand 1989; 60: 523-5.
5. Smiley P, Wasilewski SA. Arthroscopic synovectomy. Arthroscopy 1990; 6: 18-23.
6. Klug S, Whittmann G, Weseloh G. Arthroscopic synovectomy of the knee joint in early cases of rheumatoid arthritis: follow-up results of a multicenter study. Arthroscopy 2000; 16: 262-7.
7. Gibbons CE, Gosal HS, Bartlett J. Long-term results of arthroscopic synovectomy for seropositive rheumatoid arthritis: 6-16 year review. Int Orthop 2002; 26: 98-100.
8. Bogoch ER, Erica LM. Bone abnormalities in the surgical treatment of patients with rheumatoid arthritis. Clin Orthop 1999; 366: 8-21.
9. Figgie HE, Brody GA, Inglis AE, Sculco TP, Goldberg VM, Figgie MP. Knee arthrodesis following total knee arthroplasty in rheumatoid arthritis. Clin Orthop 1987; 224: 237-43.
10. Heck DA, Robinson RL, Partridge CM, Lubitz RM, Freund DA. Patient outcomes after knee replacement. Clin Orthop 1998; 356: 93-110.
11. Fortin PR, Clarke AE, Joseph L, *et al*. Outcomes of total hip and knee replacement: preoperative functional status predicts outcomes at six months after surgery. Arthritis Rheum 1999; 42: 1722-8.
12. Aglietti P, Buzzis R, Segoni F, Zaccherotti F. Insall-Burstein posterior-stabilized knee prosthesis in rheumatoid arthritis. J Arthroplasty 1995; 10: 217-5.
13. Nafei A, Kristensen O, Knudson HM, Hvid I. Survivior-ship analysis of cemented total condylar knee arthroplasty. J Arthroplasty 1996; 11: 7-10.
14. Rodriguez JA, Saddler S, Edelman S, Ranawat CS. Long-term results of total knee arthroplasty in class 3 and 4 rheumatoid arthritis. J Arthroplasty 1996; 11: 141-5.
15. Rand JA, Ilstrup DM. Survivorship analysis of total knee arthroplasty. Cumulative rates of survival of 9200 total knee arthroplasties. J Bone Joint Surg Am 1991; 73: 397-409.
16. Elke R, Meier G, Warnke K, Morscher E. Outcome analysis of total knee-replacements in patients with rheumatoid arthritis versus osteoarthritis. Arch Orthop Trauma Surg 1995; 114: 330-4.
17. Scuderi GR, Insall JN, Windsor RE, Moran MC. Survivorship of cemented knee replacements. J Bone Joint Surg Br 1989; 71: 798-803.
18. Laskin RS, Beksac B, Phongjunakorn A, *et al*. Minimally invasive total knee replacement through a mini-midvastus incision: an outcome study. Clin Orthop 2004; 428: 74-81.

19. Poss R, Ewlad FC, Thomas WH, Sledge CB. Complications of total hip-replacement arthorplasty in patients with rheumatoid arthritis. J Bone Joint Surg Am 1976; 58: 1130-3.